

Page No.

Anatomical Terminology

Bone Markers

* Directional & Positional Terminology :-

1. Anterior (ventral) : Toward the front of the body

2. Posterior (dorsal) : Toward the back of the body

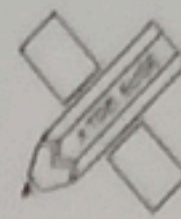
3. Superior (cranial) : Toward the head or upper part of a structure.

4. Inferior (caudal) :- Toward the feet or lower part of a structure.

5. Medial :- Toward the midline of the body.

6. Lateral :- Away from the midline of the body.

7. Proximal :- Nearer to the trunk or point of origin (e.g. the shoulder is proximal to the elbow).



8. Distal: Further from the trunk or point of the origin
9. Dorsal: Refers to the back / top surface of the hand or foot.
10. Ventral: Refers to the front / anterior surface of the body.

*: General Bone Markers

11. Tuberosity: A large, rounded, usually roughened elevation (e.g. Tibial tuberosity).
12. Crest: A prominent ridge or border of a bone (e.g. Iliac crest)
13. Foramen: An opening or hole through a bone for nerves and blood vessels.
14. Fossa: A shallow depression or hollow in a bone
15. Condyle: A rounded articular projection

that forms a joint.

Epicondyle :- A projection that forms a joint.

Suture :- An immovable fibrous joint between the bones of the skull.

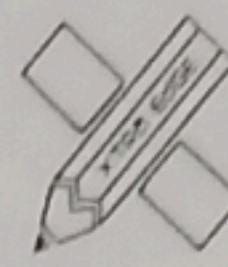
Specific Palpable Land Marks

1. Acromion :- The lateral extension of the spine of the scapula the point of the shoulder.

9. Olecranon :- The large process at the proximal end of the ulna, the point of the elbow.

20 Patella :- The sesamoid bone (kneecap) located within the quadriceps tendon.

21 Xiphoid process :- The small cartilaginous



lower tip of the sternum.

Iliac crest! The superior margin of the ilium (hip bone)

Greater Trochanter! A large, blunt projection on the lateral proximal femur.

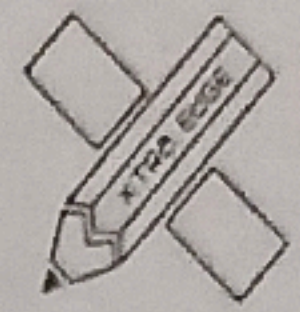Lateral malleolus! The bony prominence on the outer side of the ankle (distal fibula)

Mastoid process! The conical projection of the temporal bone behind the ear.

Mind Map!

25 Bone Marker

- ↳ Anterior (Front)
- ↳ Posterior (Back)
- ↳ Superior (Above)
- ↳ Inferior (Below)
- ↳ Medial (Towards midline)
- ↳ Lateral (Away from midline)
- ↳ Proximal (Near trunk)
- ↳ Distal (Away from trunk)
- ↳ Dorsal (Back of hand/foot)
- ↳ Ventral (Front of body)
- ↳ Acromion (Shoulder blade)
- ↳ Olecranon (Elbow bone)
- ↳ Patella (Knee cap)
- ↳ Tuberosity (Bony prominence)
- ↳ Crest (Ridge on bone)
- ↳ Foramen (Opening in bone)
- ↳ Fossa (Depression in bone)
- ↳ Condyle (Joint surface)
- ↳ Epicondyle (Bony projection)
- ↳ Suture (Joint b/w bones)
- ↳ Xiphoid process (Lower sternum)
- ↳ Iliac crest (Hip bone)
- ↳ Greater Trochanter (Femur)
- ↳ Lateral malleolus (Ankle bone)



Date. / /

Page No. 12

↳ Mastoid process (skull bone)